



## Brief report

## Evaluation of liver fibrosis by transient elastography in methotrexate treated patients

Almudena Barbero-Villares<sup>a</sup>, Jorge Mendoza<sup>a</sup>, María Trapero-Marugan<sup>a</sup>, Isidoro Gonzalez-Alvaro<sup>b</sup>, Esteban Daudén<sup>c</sup>, Javier P. Gisbert<sup>a</sup>, Ricardo Moreno-Otero<sup>a,\*</sup>

<sup>a</sup>Servicio de Aparato Digestivo y Centro de Investigación Biomédica en Red de Enfermedades Hepáticas y Digestivas (CIBEREHD), Hospital Universitario de La Princesa, Universidad Autónoma de Madrid, Madrid, Spain

<sup>b</sup>Servicio de Reumatología, Hospital Universitario de La Princesa, Universidad Autónoma de Madrid, Madrid, Spain

<sup>c</sup>Servicio de Dermatología, Hospital Universitario de La Princesa, Universidad Autónoma de Madrid, Madrid, Spain

## ARTICLE INFO

## Article history:

Received 19 July 2010

Accepted 14 December 2010

Available online 29 June 2011

## Keywords:

Transient elastography

FibroScan<sup>®</sup>

Liver fibrosis

Methotrexate

Rheumatoid arthritis

Inflammatory bowel disease

Psoriasis

## ABSTRACT

**Background and aims:** Methotrexate (MTX) safety is questioned by the risk of inducing liver fibrosis (LF). As transient elastography (FibroScan<sup>®</sup>) is an effective non-invasive technique to evaluate LF, our aims were to assess LF in MTX-treated patients, to evaluate LF regarding treatment duration and cumulative dose, and to determine differences depending on the underlying disease.

**Patients and methods:** Prospective study including patients with rheumatoid arthritis, inflammatory bowel disease, and psoriasis treated with MTX. Hepatic stiffness was determined by FibroScan<sup>®</sup>. The LF cut-off values were established using METAVIR score.

**Results:** Of 53 patients, 22 were men (41.5%), mean age was 55 (15) years, 17 (32%) had rheumatoid arthritis, 18 (34%) inflammatory bowel disease, and 18 (34%) psoriasis. Mean MTX cumulative dose was 1,805 (1,560) mg, and mean treatment duration was 178 weeks. Mean hepatic stiffness was 6.19 (2.43) KPa. In 49 patients (92.5%), absence/mild LF was found ( $F \leq 2$ ), and 4 patients (7.5%) had advanced LF ( $F \geq 3$ ). Treatment duration or cumulative doses of MTX were not associated with LF.

**Conclusions:** Regarding LF development, MTX therapy is safe. FibroScan<sup>®</sup> is useful for monitoring LF in MTX-treated patients.

© 2010 Elsevier España, S.L. All rights reserved.

### Evaluación de la fibrosis hepática mediante elastografía transitoria en pacientes tratados con metotrexato

## RESUMEN

**Fundamento y objetivos:** La seguridad del metotrexato (MTX) está en entredicho debido al riesgo de inducción de fibrosis hepática (FH). Como la elastografía de transición (FibroScan<sup>®</sup>) es una técnica no invasiva eficaz para evaluar la FH, nos planteamos como objetivos la valoración de la FH en enfermos tratados con MTX, su relación con la duración del tratamiento y la dosis acumulada, y su dependencia de la enfermedad de base.

**Pacientes y métodos:** Se ha realizado un estudio prospectivo incluyendo pacientes tratados con MTX por artritis reumatoide, enfermedad inflamatoria intestinal y psoriasis. El grado de elasticidad hepática se midió por FibroScan<sup>®</sup>. Los valores de corte para la FH se establecieron de acuerdo con el índice METAVIR.

**Resultados:** Se incluyeron 53 pacientes (22 varones, edad media de 55 [15] años) con las siguientes enfermedades: artritis reumatoide en 17 (32%), enfermedad inflamatoria intestinal en 18 (34%) y psoriasis en 18 (34%) pacientes. La dosis media acumulada de MTX fue de 1.805 (1.560) mg y el tiempo medio de duración del tratamiento de 178 semanas. El valor medio de la elastografía hepática fue de 6,19 (2,43) KPa. En 49 pacientes (92%) se apreció ausencia o ligera fibrosis ( $F \leq 2$ ) y solo 4 (7,5%) pacientes presentaron una fibrosis avanzada ( $F \geq 3$ ). No se apreciaron diferencias significativas según la duración del tratamiento o la dosis acumulada de MTX.

## Palabras clave:

Elastografía hepática

FibroScan<sup>®</sup>

Fibrosis hepática

Metotrexato

Artritis reumatoide

Enfermedad inflamatoria intestinal

Psoriasis

\* Corresponding author.

E-mail address: rmoreno.hlpr@salud.madrid.org (R. Moreno-Otero).

**Conclusiones:** El tratamiento con MTX es seguro en lo que respecta a la inducción de FH. El FibroScan® es una técnica eficaz para monitorizar la FH en los pacientes tratados con MTX.

© 2010 Elsevier España, S.L. Todos los derechos reservados.

## Introduction

Methotrexate (MTX) has been used in oncologic therapy and in chronic inflammatory diseases. Hepatic fibrosis is the most concerning side effect in long-term treatment.

Liver biopsy remains the "gold standard" technique for fibrosis evaluation, but some limitations exist.<sup>1,2</sup> Recently, several reports have drawn attention to the possibility of reliably evaluating liver fibrosis non-invasively.<sup>3</sup> Transient elastography (TE) (FibroScan®) is a novel non-invasive method, without side effects, and it allows sequential measurements during follow-up.<sup>3-5</sup> Our aims were to evaluate liver fibrosis by TE in patients with different chronic inflammatory diseases (rheumatoid arthritis [RA], inflammatory bowel disease [IBD], and psoriasis) treated with MTX. We also aimed to study the presence of significant fibrosis ( $F > 2$ ) in MTX-treated patients; and to compare the differences existing in the stage of liver fibrosis and its relationship with MTX in patients with different diseases.

## Patients and methods

This was an observational prospective study, including RA, IBD and psoriasis patients treated with MTX. Epidemiological, clinical and laboratory data were obtained. Duration of treatment and cumulative dose of MTX were also reported.

TE was performed by a single gastroenterologist blinded to other data. Measurements were performed into the right lobe of the liver, through one intercostal space with the patient laying on his/her back and the right arm on maximum abduction. Patients without at least 10 valid measurements were excluded. Informed consent was obtained from every patient and the study was approved by the ethics committee.

The cut-off values for hepatic fibrosis (METAVIR score) were established choosing the values with the best sensitivity-specificity ratio for each stage of fibrosis. No study that establishes specific cut-off values for hepatic fibrosis in MTX-treated patients exists. The largest and most homogeneous studies included patients with chronic viral hepatitis; therefore, we used the cut-off values established by these trials. The cut-off values chosen were:  $F \geq 2$ : 7.1 KPa (sensitivity 67%, specificity 89%);  $F \geq 3$ : 9.5

KPa (sensitivity 84%, specificity 85%); and  $F4$ : 14.5 (sensitivity 84%, specificity 94%), according to previous publications.<sup>3</sup>

Statistical study: ANOVA test and  $\chi^2$  and Kruskal-Wallis for non-parametric variables such as liver stiffness, were used. Kendall's tau- $\beta$  was used for correlations. Multiple logistic regression analysis was used to evaluate the presence of significant fibrosis ( $F \geq 2$ ) in the three disease groups.

## Results

A total of 64 patients were evaluated, 11 (17%) of them being excluded due to technical failure –mean body mass index (BMI) of 33.6%  $\text{kg/m}^2$  (range: 23.8-43  $\text{kg/m}^2$ )–. Therefore, 53 patients were finally included, 22 were men (41.5%) and 31 women (58.5%), with a mean age of 55 (15) years (range: 20-81 years) and a mean BMI of 25 (4)  $\text{kg/m}^2$ .

Regarding toxic habits, 13 patients (25.5%) were smokers and 2 patients (3.8%) were drinkers of  $\geq 30$  g alcohol per day. Three patients had chronic viral hepatitis (2 hepatitis C virus and 1 hepatitis B virus) without any clinical or biochemical data of advanced liver disease.

Of the 53 patients studied, 17 (32.1%) had RA, 18 (34%) IBD (4 ulcerative colitis and 14 Crohn's disease), and 18 (34%) psoriasis. The mean evolution time of diseases was 11 (7) years. The mean cumulative dose of MTX was 1,805 (1,560) mg (range: 30-5,763 mg), with a treatment mean duration of 178 weeks (range: 2-544 weeks). A 55.8% of patients were still on MTX, whereas the remaining had finished the treatment at the time of the study.

The mean value of liver stiffness obtained for all the patients was 6.19 (2.43) KPa (range: 2.10-14.50 KPa), with a mean success rate of 69 (29%). According to the METAVIR score, 49 patients (92.5%) were found to have absence or mild fibrosis ( $F \leq 2$ ), and 4 patients (7.5%) had advanced fibrosis (F3). Only one patient was classified as F4 (stiffness  $\geq 14.5$  KPa), compatible with cirrhosis. No correlation between liver stiffness and cumulative dose of MTX was observed.

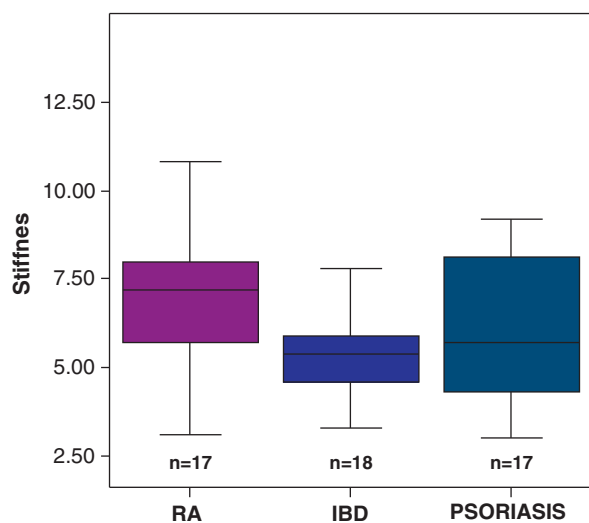
Patients were analyzed regarding their disease (RA, IBD and psoriasis), and differences between groups are summarized in Table 1. There were statistically significant differences in the cumulative dose of MTX (higher in RA, with a mean dose of 2,635

**Table 1**  
Results and differences found between the studied diseases.

	Rheumatoid arthritis (n = 17). Mean (DE)	IBD (n = 18). Mean (DE)	Psoriasis (n = 18). Mean (DE)	P
Women	12	11	8	N.S.
Age (years old)	62 (16)	49 (11)	54 (17)	N.S.
BMI ( $\text{kg/m}^2$ )	25 (4)	26 (5)	26 (3)	N.S.
Time of evolution of disease (years)	7 (4)	14 (6)	13 (8)	.008
Treatment duration (weeks)	310 (161)	151 (161)	81 (109)	.000
Cumulative dose of MTX (mg)	2,635 (1,581)	1,622 (1,339)	1,168 (1,466)	.016
AST (U/L)	24 (11)	22 (7)	21 (9)	N.S.
ALT (U/L)	23 (11)	22 (13)	26 (16)	N.S.
Alk Phos (U/L)	77 (29)	78 (30)	64 (26)	N.S.
GGT (U/L)	26 (14)	34 (57)	16 (7)	N.S.
Albumin	4.11 (0.25)	4.19 (0.34)	4.32 (0.29)	N.S.
Platelets/ $\text{mm}^3$	239,058 (68,515)	279,611 (65,811)	220,352 (46,868)	N.S.
INR	1.02 (0.09)	1.02 (0.06)	1.04 (0.03)	N.S.
Stiffness (KPa)	7.10 (2.89)	5.73 (2.19)	5.78 (2.04)	N.S.
Success (%)	70 (29)	67 (29)	71 (29)	N.S.

Alk Phos: alkaline phosphatase; ALT: alanine aminotransferase; AST: aspartate aminotransferase; GGT: gamma glutamil-transpeptidase; IBD: inflammatory bowel disease; MTX: methotrexate; N.S.: non significant.

Normal values: AST (4-38 U/L), ALT (5-41 U/L), Alk Phos (40-129 U/L), GGT (11-49 U/L), Albumin (3.4-4.8 g/dl), Platelets (200,000-400,000/ $\text{mm}^3$ ), INR (0.8-1.2).



RA (rheumatoid arthritis): 7.10 (2.89) KPa;  
 IBD (inflammatory bowel disease): 5.73 (2.19)  
 KPa; psoriasis: 5.78 (2.04) KPa;  $p=0.173$  (non significant).

**Figure 1.** Liver stiffness assessed by FibroScan<sup>®</sup>. RA (rheumatoid arthritis): 7.10 (2.89) KPa; IBD (inflammatory bowel disease): 5.73 (2.19) KPa; psoriasis: 5.78 (2.04) KPa;  $p = 0.173$  (non significant).

(1,581) mg, compared to 1,622 (1,339) mg in IBD and 1,168 (1,466) mg in psoriasis,  $P = .016$ ). No other differences between groups were observed. No statistically significant differences related to stiffness or fibrosis stage measured by FibroScan<sup>®</sup> between groups were observed (Fig. 1).

The presence of significant fibrosis ( $F \geq 2$ ) was assessed by multiple logistic regression analysis (including age, sex, BMI, cumulative dose, duration of treatment and underlying disease), and no significant differences between groups were found.

## Discussion

A relationship between MTX-based therapy and the development of liver fibrosis has been reported.<sup>2,3</sup> Liver biopsy remains the "gold standard" investigation for evaluation of hepatic fibrosis, but several limitations are inherent to its application. The magnitude of hepatic stiffness has been shown to correlate significantly with the stage of hepatic fibrosis. Optimal cut-off values for significant fibrosis in patients with chronic hepatitis C (stage of fibrosis  $\geq 2$ ) have been reported to range from 7.1 to 8.7 KPa.<sup>3,4</sup>

We evaluated the relationship between treatment with MTX and the development of liver fibrosis in patients with non-oncologic diseases by TE (FibroScan<sup>®</sup>). In most patients (92.5%), absence or minimal fibrosis was found and significant fibrosis ( $F \geq 2$ ) only detected in 4 (7.5%) patients. Similar to former results, no correlation between MTX dose and liver stiffness was found and no differences in liver stiffness between disease groups, despite heterogeneous diseases, evolution time, treatment duration and cumulative MTX dose, were observed (Table 1). Recent studies using TE to assess liver fibrosis in patients treated with MTX<sup>6-8</sup> have obtained similar results and are comparable to those using liver biopsy or serologic markers of fibrosis.<sup>6-8</sup> An advanced stage of fibrosis ( $F \geq 3$ ) was found in 4 (7.5%) of our MTX-treated patients, with only one case of cirrhosis ( $F = 4$ ). This case was documented as secondary to alcohol abuse. None of the other 4 patients with known liver disease presented advanced fibrosis in TE measurements. These results strengthen the security of MTX regardless the presence of liver disease. Therefore, we can conclude that the development of significant liver fibrosis in patients with

long-term MTX-based therapy appears to be much more unusual than traditionally thought, even with high doses of MTX.

TE has some limitations in obese patients and in patients with ascites. We obtained a relatively high rate of technical failure (17%) compared to other studies. Those patients in whom it was not possible to assess liver stiffness had a mean BMI of 33.6 kg/m<sup>2</sup>, an important grade of obesity that obviously influenced the results.

An update of current guidelines regarding monitoring of liver function<sup>6-8</sup> in these patients (including the indications for a liver biopsy) has been proposed. In addition, this article claims that the new non-invasive techniques to assess liver fibrosis might reduce the need of obtaining a biopsy from these patients. Liver biopsy was not included in the design of the present study, and this could be a limitation. In patients with advanced liver disease, we performed a careful investigation and found no data of liver dysfunction except in the patient with known cirrhosis.

TE facilitates diagnostic and therapeutic decisions without the need to undertake repeat liver biopsies. TE is well tolerated and accepted by patients. Its characteristics suggest that it will become an increasingly useful investigation in clinical practice, particularly in therapeutic trials, and especially when patients are reluctant to give consent for one or more repeated liver biopsies.<sup>3-5,9,10</sup>

In conclusion, our data supports that MTX does not lead to an important development of liver fibrosis when prescribed at common doses, without significant differences between patients with RA, IBD and psoriasis. Moreover, FibroScan<sup>®</sup> appears useful for the evaluation and long-term monitoring of liver fibrosis in MTX-treated patients with chronic inflammatory diseases.

## Funding

Supported by grants from Fundación Mutua Madrileña and CIBEREHD (funded by Instituto de Salud Carlos III, Madrid, Spain).

## Conflict of interest

The authors disclose no conflict of interest.

## References

1. Bedossa P, Dargere D, Paradis V. Sampling variability of liver fibrosis in chronic hepatitis C. *Hepatology*. 2003;38:1449-57.
2. Antón MD, Roselló E, Gómez F, Paredes JM, López A, Moreno-Osset E. Hepatic steatosis in chronic hepatitis C: study of risk factors and relationship with the fibrosis stage. *Med Clin (Barc)*. 2009;132:574-9.
3. Castera L, Vergniol J, Foucher J, Le Bail B, Chanteloup E, Haaser M, et al. Prospective comparison of transient elastography, Fibrotest, APRI, and liver biopsy for the assessment of fibrosis in chronic hepatitis C. *Gastroenterology*. 2005;128:343-50.
4. Mendoza J, Gómez-Domínguez E, Moreno-Otero R. Transient elastography (Fibroscan), a new non-invasive method to evaluate hepatic fibrosis. *Med Clin (Barc)*. 2006;126:220-2.
5. Gómez-Domínguez E, Mendoza J, Rubio S, Moreno-Monteagudo JA, García-Buey L, Moreno-Otero R. Transient elastography: a valid alternative to biopsy in patients with chronic liver disease. *Aliment Pharmacol Ther*. 2006;24:513-8.
6. Laharie D, Zerbib F, Adhoute X, Boué-Lahorgue X, Foucher J, Castéra L, et al. Diagnosis of liver fibrosis by transient elastography (Fibroscan) and noninvasive methods in Crohn's disease patients treated with methotrexate. *Aliment Pharmacol Ther*. 2006;23:1621-8.
7. Aithal GP, Haugk B, Das S, Card T, Burt AD, Record CO. Monitoring methotrexate-induced hepatic fibrosis in patients with psoriasis: are serial liver biopsies justified? *Aliment Pharmacol Ther*. 2004;19:391-9.
8. Berends MA, Snoek J, De Jong EM, Van Krieken JH, De Knecht RJ, Van Oijen MG, et al. Biochemical and biophysical assessment of MTX-induced liver fibrosis in psoriasis patients: Fibrotest predicts the presence and Fibroscan predicts the absence of significant liver fibrosis. *Liver Int*. 2007;27:639-45.
9. Moreno-Otero R, Trapero-Marugán M, Mendoza J. Liver fibrosis assessment by transient elastography in hepatitis C patients with normal alanine aminotransferase. *Gut*. 2006;55:1055-6.
10. Gomez-Dominguez E, Mendoza J, Garcia-Buey L, Trapero M, Gisbert JP, Jones EA, et al. Transient elastography to assess hepatic fibrosis in primary biliary cirrhosis. *Aliment Pharmacol Ther*. 2008;27:441-7.